

An Adverse Event Associated with Antifungal Therapy: Presentation as Posterior Reversible Encephalopathy Syndrome

Ayşın Kısabay Ak¹ , Serpil Erbüyün² , Deniz Heppekcan³ , Melike Batum¹ , Recep Boyacı⁴ ,
Hatice Maviöğlü¹ , Demet Aydın Tok³ 

¹Department of Neurology, Celal Bayar University School of Medicine, Hafsa Sultan Hospital, Manisa, Turkey

²Clinic of Anesthesiology and Reanimation, Manisa State Hospital, Manisa, Turkey

³Department of Anesthesiology and Reanimation, Celal Bayar University School of Medicine, Hafsa Sultan Hospital, Manisa, Turkey

⁴Department of Anesthesiology and Reanimation, Celal Bayar University School of Medicine, Hafsa Sultan Hospital, Manisa, Turkey

Cite this article as: Kısabay Ak A, Erbüyün S, Heppekcan D, et al. An adverse event associated with antifungal therapy: Presentation as posterior reversible encephalopathy syndrome. Yoğun Bakım Derg 2018; 9 (2): 59-62.

This study was presented at the 51st National Congress of Neurology (2nd November 2015, Antalya, Turkey).

Corresponding Author:

Ayşın Kısabay Ak

E mail: aysinkisabay@hotmail.com

©Copyright 2018 by Turkish Society of Medical and Surgical Intensive Care Medicine - Available online at www.dcyogunbakim.org

Author Contributions: Concept – D.A.T., A.K.A.; Design – D.A.T., A.K.A., H.M., S.E., D.H.; Supervision – A.K.A., D.H., M.B.; Resources – A.K.A., M.B., R.B., S.E.; Materials – D.A.T., H.M., R.B.; Data Collection and/or Processing – A.K.A., M.B., R.B.; Analysis and/or Interpretation – D.A.T., H.M., D.H.; Literature Search – D.A.T., A.K.A., S.E.; Writing Manuscript – D.A.T., A.K.A., H.M.; Critical Review – D.A.T., H.M.

Abstract

Posterior reversible encephalopathy syndrome (PRES) is a diagnosis characterized by headache, changes in consciousness, epileptic seizures, visual symptoms (decreased visual acuity and blurred vision), vasospasm, and perfusion abnormalities in the posterior systemic vessels of the brain. The most common clinical findings of PRES include headache, epileptic seizure, altered consciousness, motor deficits, and loss of vision. In the patient who presented with symptoms similar to those in PRES after the use of anidulafungin and had a history of trauma, other causes of PRES (like carotid and/or vertebral artery dissection, intra-abdominal trauma, and head trauma etc.) were excluded. In our case, visual disturbance was assessed as being secondary to central nervous system pathology. There are no similar cases in the literature that presented with clinical features of PRES and normal imaging findings. The primary aim of this study was to draw attention to the fact that anidulafungin may cause symptoms similar to those in PRES.

Keywords: Posterior reversible encephalopathy syndrome headache, epileptic seizure, cortical blindness, side effect

Received: 15.02.2018 • **Accepted:** 04.06.2018

Available Online Date: 16.08.2018

Informed Consent: Written informed consent was obtained from patient's parents and verbal informed consent was obtained from the patient after the treatment and recovery.

Peer-review: Externally peer-reviewed.

Conflict of Interest: The authors have no conflicts of interest to declare.

Financial Disclosure: The authors declared that this study has received no financial support.

Introduction

Posterior reversible encephalopathy syndrome (PRES) is associated with headache, changes in consciousness, epileptic seizure, and visual symptoms (blurred vision and decrease in visual acuity) and is a diagnosis characterized by vasospasm and perfusion disorder in the posterior system vessels of the brain. This clinical picture was first defined by Hinchey et al. (1) in 1996.

The most common clinical findings in PRES are headache, seizures, clouding of consciousness, motor deficits and loss of vision (2).

Its causes by frequency are hypertensive encephalopathy, preeclampsia associated with the partum and postpartum period, eclampsia, HELPP (hemolysis elevated liver enzymes low platelets) syndrome, drugs used (immunosuppressive drugs, cytotoxic drugs, high dose steroid use), metabolic causes (kidney failure, liver failure), hematologic causes (thrombotic thrombocytopenic purpura, massive blood transfusion), collagen vascular diseases, HIV infection, acute intermittent porphyria and organ transplantation (2-4).

In terms of physiopathology, fibrinoid necrosis, interstitial edema, and petechial microhemorrhage

were detected in the arterial walls. However, no infarct finding was encountered. In angiography studies, especially during a hypertensive crisis, it has been shown that vasospasm develops especially in arteries in the posterior circulation (5).

According to the hyperperfusion theory which explains the pathophysiology, in spontaneous and sudden blood pressure elevations, when cerebral autoregulation is exceeded, arterioles undergoing vasospasm cannot contract more and are forced to dilate with the increased blood pressure. This also leads to changes in perfusion pressure and thus to the disruption of the blood-brain barrier. In this case, plasma and erythrocytes move from the intravascular region to the extravascular region and lead to the formation of vasogenic edema (4, 5).

Vasogenic edema developing in the brain tissue constitutes the basis of pathophysiology. Studies and available pieces of evidence indicate that the lesions observed in PRES cases are mainly due to vasogenic edema rather than cytotoxic edema. It is completely reversible after the cause is eliminated (2, 4, 5).

In the differential diagnosis of PRES, hypertensive encephalopathy, ischemic and hemorrhagic cerebral events, infectious causes (herpes virus encephalitis), central nervous system vasculitis, demyelinating diseases, and metabolic causes (hypoglycemia and hyponatremia) should be considered, and these diagnoses should be excluded by a detailed examination (3, 5, 6).

In neuroimaging, the main finding is especially in the posterior white matter, and symmetrical reversible edema (occipital, parietal lobe, and posterior fossa structures) is mostly observed in the adult population.

Furthermore, sometimes symmetrically localized edema is also present in the cortex. For this reason, it is essential to administer antiedema therapy. Moreover, antiepileptic and antihypertensive therapies are also included in the basic approach (5, 6).

When epileptic seizures, headache, and visual field findings are brought under control in most of the cases with PRES, it is benign with good prognosis (2, 5). It has been remarkable that clinical and radiological abnormalities are reversible after the improvement of activating factors and appropriate treatment (2, 4, 5).

Case Report

In the initial assessment of a 65-year-old female patient who presented to our emergency department due to an extravehicular traffic accident, she was conscious, oriented, cooperative, and her neurological examination was normal. In the physical examination, it was determined that respiratory sounds were decreased in all segments in the right lung and there were widespread rales, and rib fracture and subcutaneous emphysema.

The patient with a body temperature of 36°C, a blood pressure of 125/62 mmHg and a pulse rate of 85/min was admitted to the anesthesia intensive care unit to be supported with mechanical ventilation due to the detection of hypoxemia in the arterial blood gas (pO_2 : 89) and the development of respiratory distress.

There was no any special feature in her medical record.

In the clinic where she was hospitalized, thoracic drainage was applied through the second left intercostal space by the thoracic surgery clinic.

The patient was evaluated by the orthopedics and traumatology clinic, right anterior shoulder dislocation was detected, and closed reduction was performed.

The cranial and cervical computed tomography (CT) taken in terms of a possible head and neck trauma was within the normal limits. There was no pathology in the head and neck region except for the laceration involving the skin, subcutaneous region, and muscles in the left temporal region.

During the clinical and routine biochemistry monitoring, no significant pathology was found except for low hemoglobin and hematocrit values (Hemoglobin (Hb): 9.8 hematocrit (Htc): 30) in the hemogram examination of the patient whose biochemistry (liver, kidney function tests, electrolytes, fasting blood sugar) values were within the normal limits. The patient was given 1 unit of erythrocyte suspension. Fluid and electrolyte support was provided. The patient was extubated after 3 days with blood gas follow-ups and was provided with oxygen support. On day 9, she had high fever; samples for blood and urine cultures were taken, and yeast growth was reported from the blood culture. On day 13, Eraxis vial (anidulafungin) 100 mg/day was initiated. On day 14, while the neurological examination was normal and blood pressure was 110/60 mmHg, the patient had a generalized tonic-clonic seizure and then complaints of nausea and vomiting. Then, a sudden loss of vision developed in both eyes.

In the neurological examination, consciousness (in the postictal period) was prone to sleep, the patient was opening her eyes with a tactile stimulus, and co-operation and orientation were partially limited. While direct and indirect light reflexes were present bilaterally, there was loss of vision to the extent that the patient was not able to perceive the light. No significant pathology was detected during the neurological examination except for the ophthalmologic examination.

The patient was evaluated by urgent cranial CT considering a possible intracranial hematoma or infarct. There was no pathology in the acute phase in CT. No antiepileptic therapy was initiated in the patient with only one seizure, and she was followed up. In the electroencephalography taken, there was paroxysmal activity disorder (paroxysmal sharp and slow waves) along with mild background slowing. No epileptic activity was observed (Figure 1). Cranial magnetic resonance imaging (MRI)-diffusion MRI and MR angiography were taken by considering possible venous thrombosis and PRES. All tests performed were within the normal limits, and venous thrombosis was excluded (Figure 2).

Bilateral carotid and vertebral artery doppler USG was taken by considering carotid dissection in the etiology of the patient evaluated in terms of developing PRES-trauma association, and it was reported normal. Cerebrovascular disease was also examined from the cardiac aspect for the etiology in terms of transient ischemic attack. The patient had a normal sinus rhythm in the ECG examination, and her echocardiographic examination was also normal.

During the neurological examination performed, the patient was conscious, and her location, time and person orientation were complete. Anidulafungin (Eraxis-Pfizer-New York//United States) vial that had been initiated a day ago was discontinued considering that the existing findings developing in the patient could be side effects due to it, and Caspofungin (Cancidas- Merck sharp &Dohme-New Jersey/ United States) 50 mg/day was initiated instead of it. No clinical deterioration was observed after the change of drug. The loss of vision of the patient improved within 1 day.

In the ophthalmological examination performed, the patient had a visual acuity to the extent that she could count fingers at 3 meters.

The patient was evaluated by the anamnesis, clinic and neurological examination and found to be consistent with the PRES clinic developing due to the drug effect.

The consent form for case reporting was obtained in writing from the patient's relative since she was hospitalized in the anesthesia intensive care unit, and then it was obtained verbally from her after clinical improvement.

Discussion

Our patient was followed in the anesthesia intensive care unit of our hospital after the traffic accident and evaluated by a neurological consultation upon the development of generalized tonic-clonic seizure and bilateral loss of vision.

Posterior reversible encephalopathy syndrome is characterized by mental status changes, headache, epileptic seizures, visual disturbances (with

normal pupillary reflex and ophthalmoscopic examination and may be accompanied by intermittent visual hallucinations) and typical perfusion disorders in the posterior system circulation of the brain (1, 2, 4, 7).

Posterior reversible encephalopathy syndrome was primarily considered because our patient had bilateral loss of vision and simultaneous seizure. The fact that the patient did not see to the extent that she was not able to perceive the light while direct and indirect light reflexes were preserved suggested that the clinic was central, and it was found to be consistent with cortical blindness. However, magnetic resonance imaging examinations were within the normal limits, and it was observed that PRES diagnosis was not supported radiologically. There was no hypertension and other causes that are primarily held responsible in the etiology of this syndrome. In the history of the patient, there was no risk factor other than trauma and the antifungal (anidulafungin) drug used.

Furthermore, distinctively, our patient who also had no history of immunosuppressive and cytotoxic drug use had the history of antifungal drug use (anidulafungin). The emergence of clinical picture one day after the initiation of the drug and the clinical improvement within 24 hours after the drug was discontinued primarily suggested the side effect of the drug.

Upon examining the literature, it is observed that PRES and trauma-associated cases have been reported (8-10). Traumas can be in the carotid and/or vertebral artery and may also originate from the intraabdominal region, kidney or pancreas. In such cases, whole-body computed tomography examination is suggested to exclude possible dissection for vertebral artery and carotid artery trauma, and carotid and vertebral artery Doppler ultrasonography, CT angiogram examination have been performed and suggested (8, 9). After intraabdominal traumas, cases with the PRES clinic developing secondarily to renal failure and pancreatic insufficiency have been reported (10). Our patient had no intraabdominal trauma history. The carotid and vertebral artery Doppler ultrasonography were performed in terms of possible carotid and vertebral artery dissection and trauma-PRES association because there was trauma in the thoracic region.

The active agent of Eraxis is anidulafungin, which is used in serious fungal infections (Candida, etc.). While the side effects of the drug are headache by 8%, drowsiness by 2%, feeling of dizziness and epileptic seizures

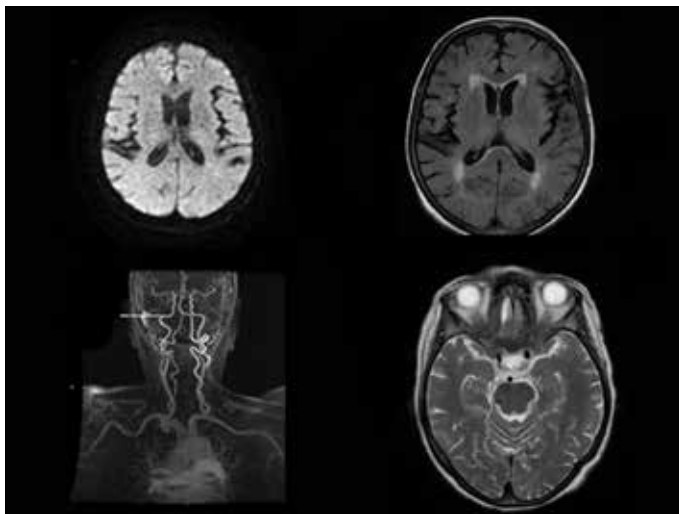


Figure 1. Cranial MRI (T2 axial, T2 flair, diffuse axial) and MR angiography

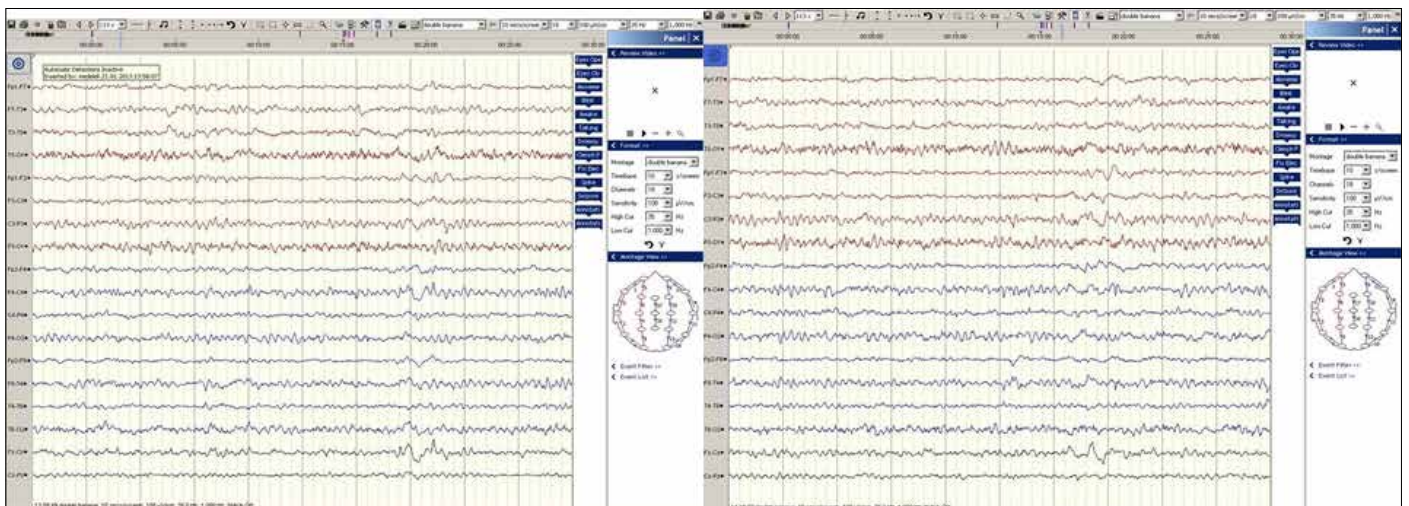


Figure 2. In the EEG examination, it is consistent with mild background slowing and the presence of paroxysmal sharp and slow discharges

by 2%, ophthalmologic side effects are rarely observed by less than 2%. Ophthalmologic side effects are eye pain, blurred vision, and a decrease in visual acuity. Regarding the side effects of the drug, epileptic seizures are common while vision disorders are uncommon. Information on by which mechanism the visual impairment occurs was not found in the literature.

Conclusion

The clinical findings of this patient were consistent with PRES, and visual impairment was due to the central effect. No case leading to the PRES like presentation and having normal imaging was encountered in the literature. Therefore, the resulting clinical presentation was most likely associated with Anidulafungin. The fact that the drug led to epileptic seizure indicates that it had central neuronal effects. It is also possible that visual impairment may be caused by the central effect.

This case was presented for the purpose of drawing attention to the fact that Anidulafungin may form a PRES-like clinical presentation. The reports of new cases in this regard may provide an additional contribution to the association.

References

1. Hinchey J, Chaves C, Appignani B, et al. A reversible posterior leukoencephalopathy syndrome. *N Engl Med* 1996; 334: 494-500. [\[CrossRef\]](#)
2. Legriel S, Pico F, Azoulay E. Understanding Posterior Reversible Encephalopathy Syndrome. *Annual Update in Intensive Care and Emergency Medicine* 2011; 631-53. [\[CrossRef\]](#)
3. Vaughan CJ, Delanty N. Hypertensive emergencies. *Lancet* 2000; 356: 411-7. [\[CrossRef\]](#)
4. Bartynski WS. Posterior reversible encephalopathy syndrome, part 1: Fundamental imaging and clinical features. *AJNR Am J Neuroradiol* 2008;29(6):1036-42. [\[CrossRef\]](#)
5. Pereira PR, Pinho J, Rodrigues M, et al. Clinical, Imagiological and etiological spectrum of posterior reversible encephalopathy syndrome. *Arq Neuropsiquiatr* 2015; 73: 36-40. [\[CrossRef\]](#)
6. Ringelstein EB, Knecht S. Cerebral Small Vessel Diseases: Manifestations In Young Women. *Curr Opin Neurol* 2006; 19: 55-62. [\[CrossRef\]](#)
7. Fugate JE, Claassen DO, Cloft HF, et al. Posterior reversible encephalopathy syndrome: associated clinical and radiologic findings. *Mayo Clin Proc* 2010; 85: 427-32. [\[CrossRef\]](#)
8. Ortega-Carnicer J, Ambrós A, Diarte JI. Reversible posterior leukoencephalopathy syndrome in a young trauma patient. *Resuscitation* 2005; 64: 119-20. [\[CrossRef\]](#)
9. Nishimura M, Hiraoka E, Kanazawa K, et al. Postpartum vertebral artery dissection with posterior reversible encephalopathy syndrome. *BMJ Case Rep* 2015; 6: 2015. [\[CrossRef\]](#)
10. Sigurta A, Terzi V, Regna-Gladin C, et al. Posterior Reversible Encephalopathy Syndrome Complicating Traumatic Pancreatitis: A Pediatric Case Report. *Medicine* 2016; 95: 3758. [\[CrossRef\]](#)